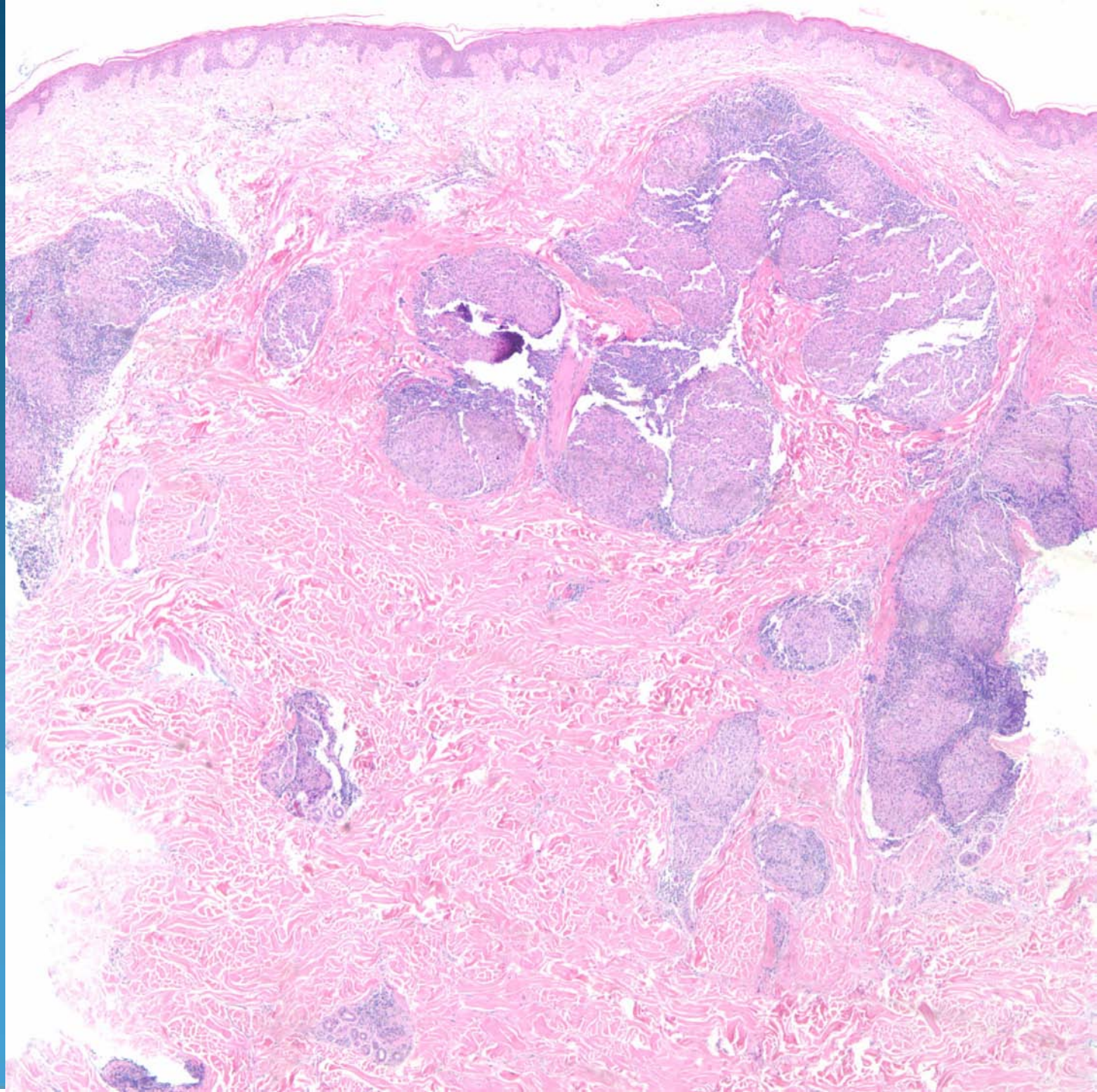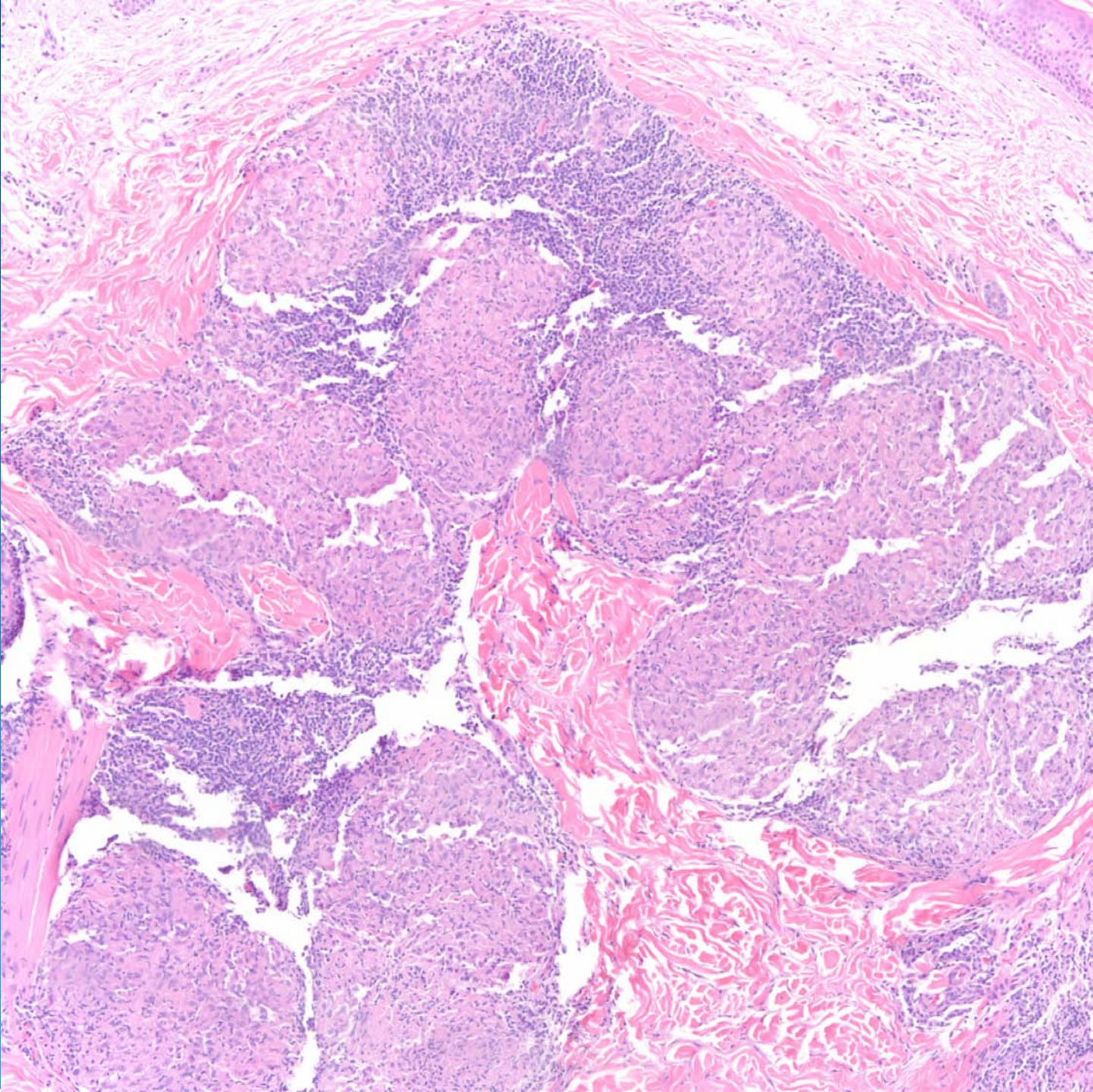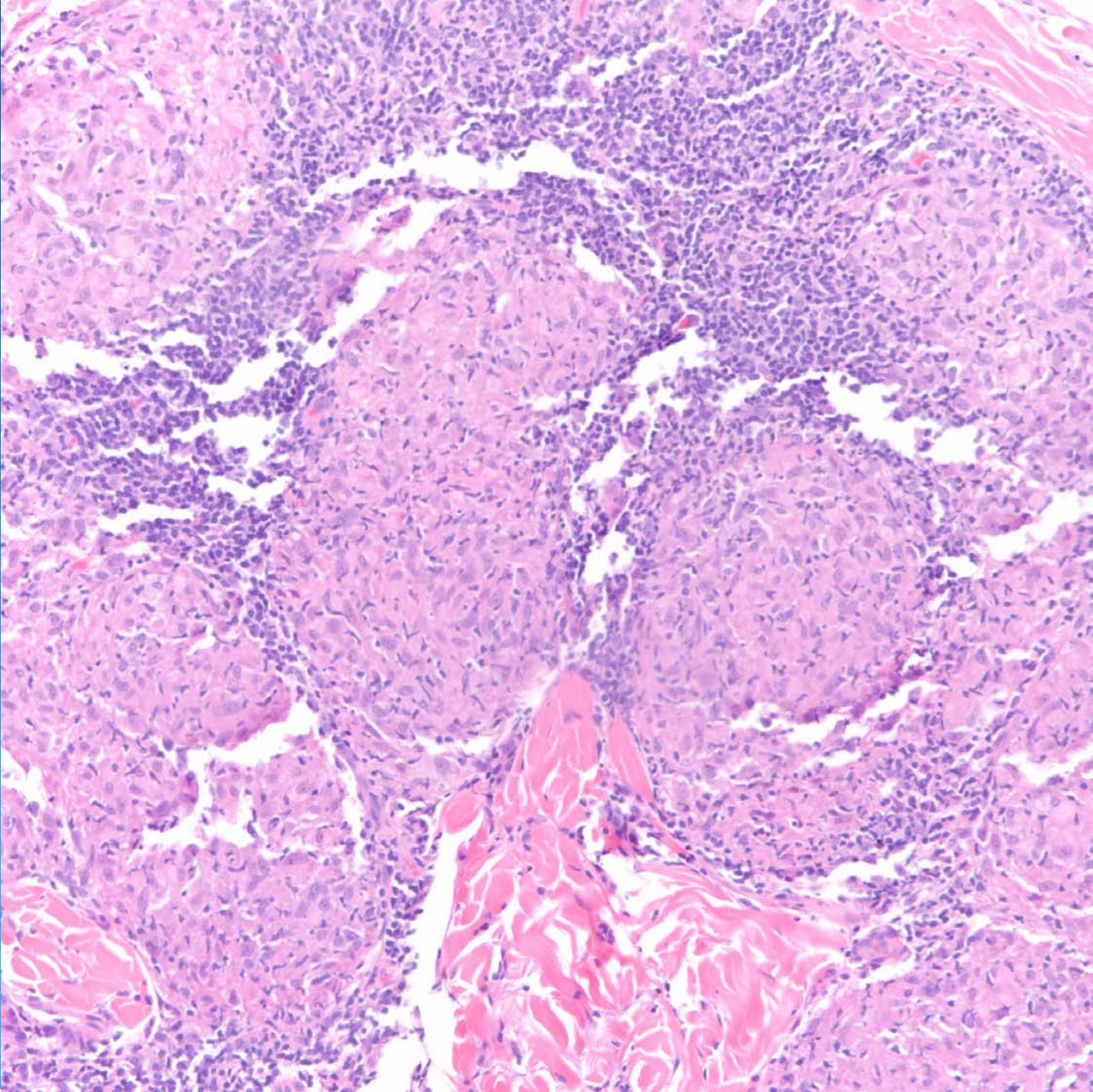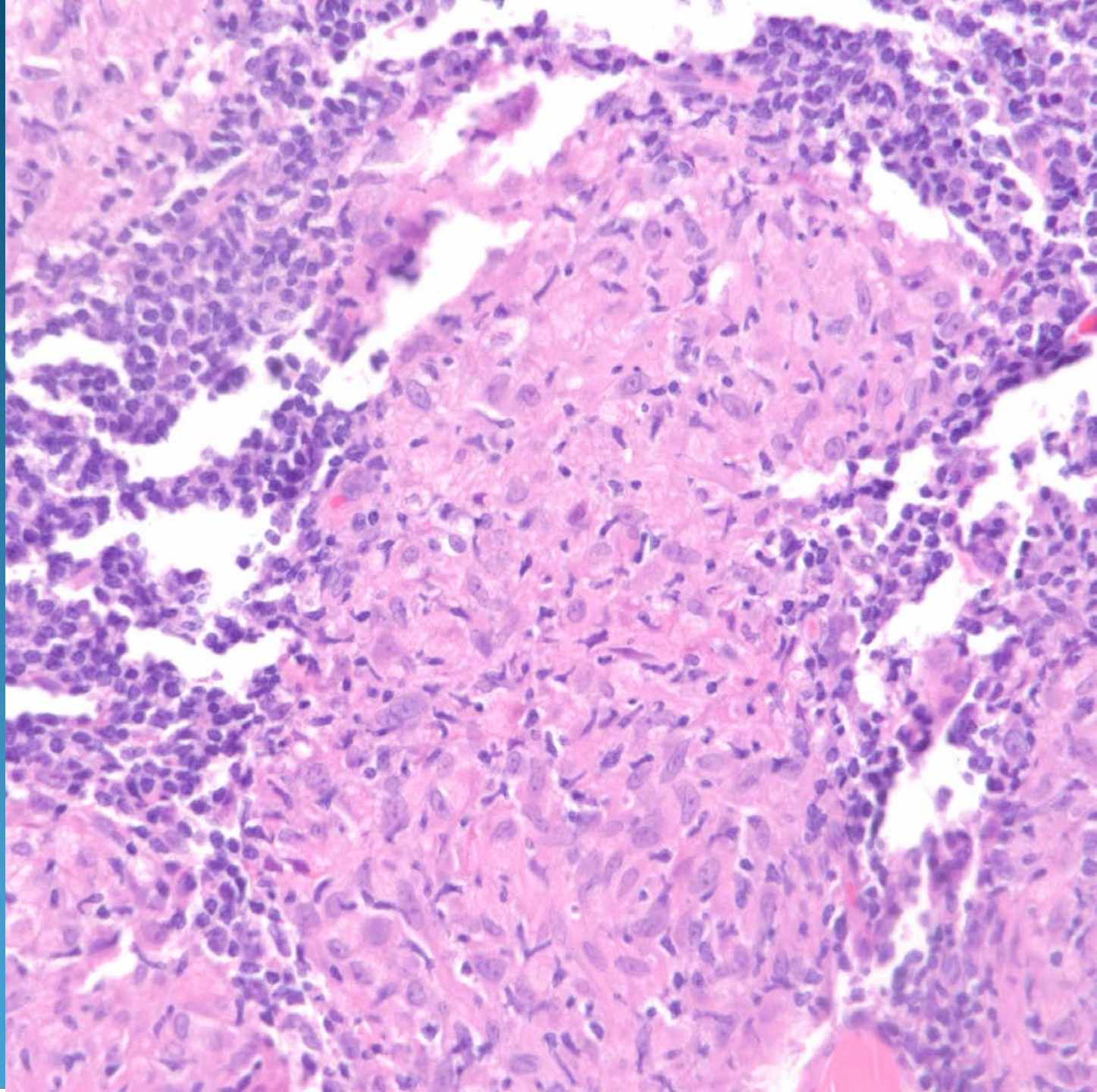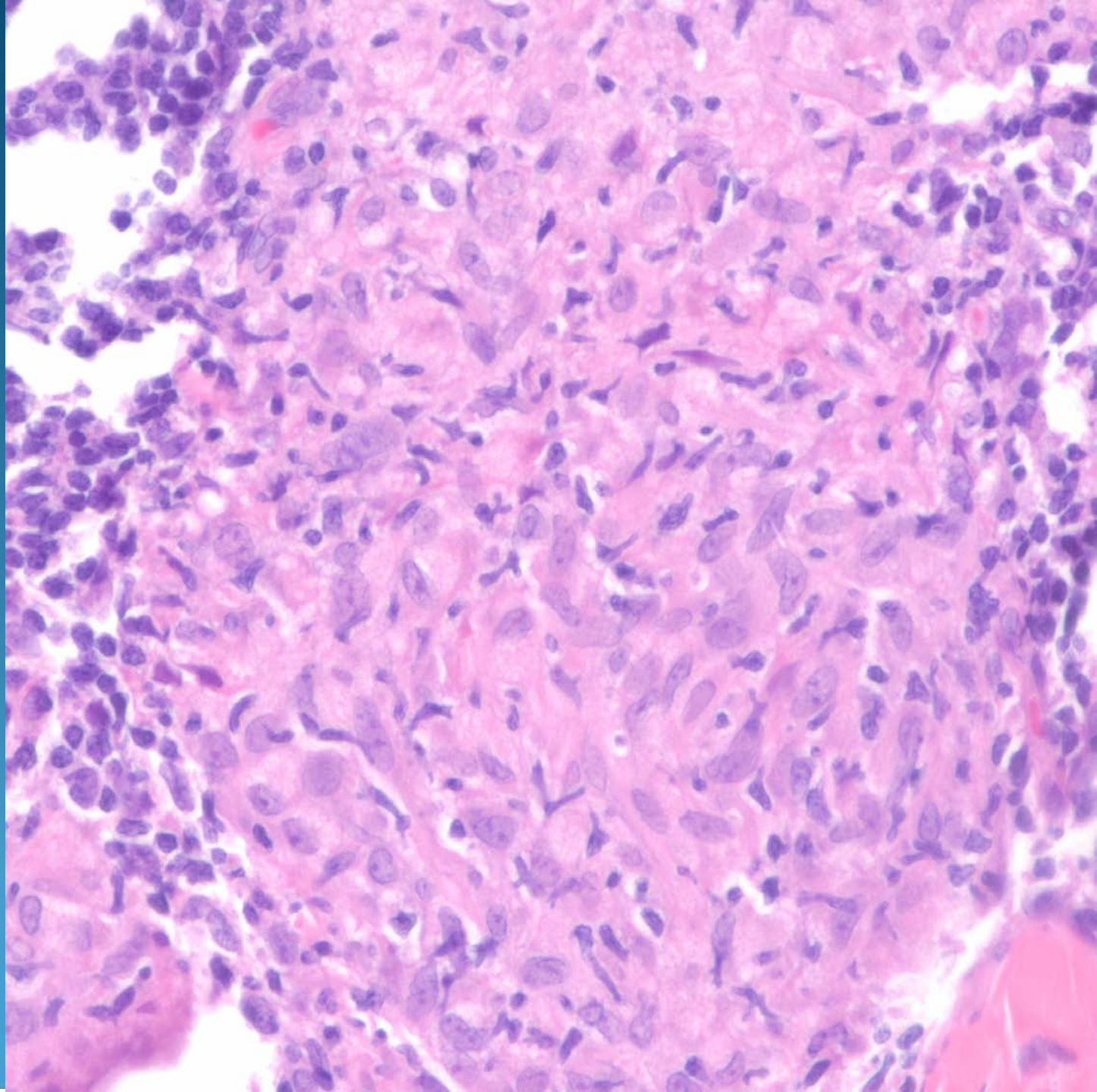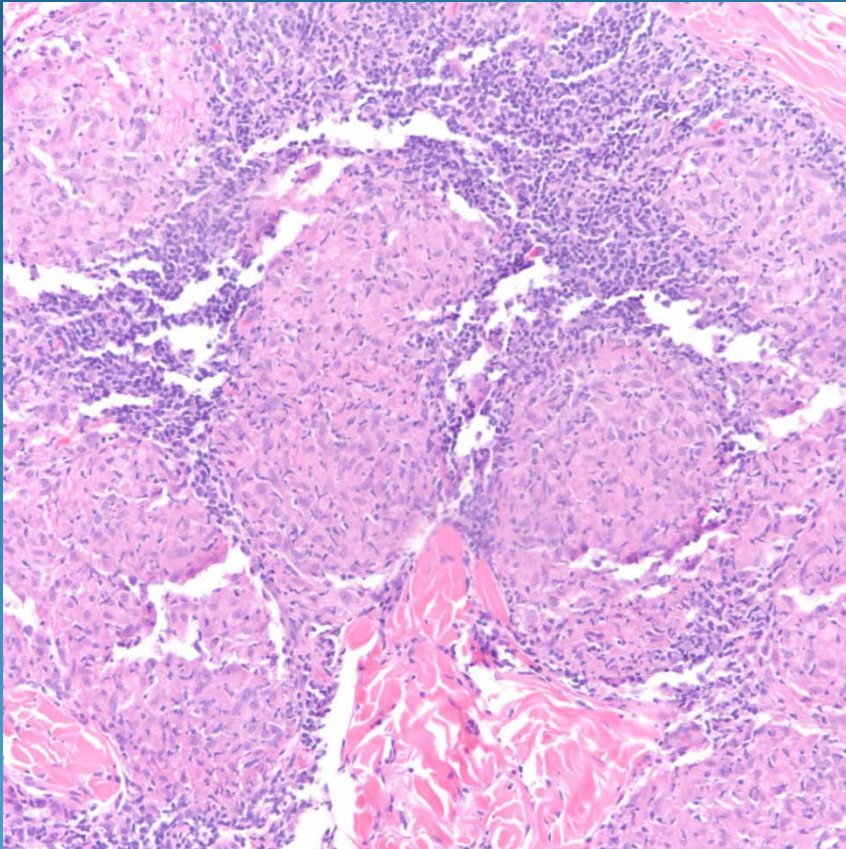


Sarcoidosis

Pearls



- Non-caseating granulomas with minimal surrounding chronic inflammation
- Beware perineural involvement, rule out tuberculoid leprosy
- Always polarize and perform AFB/FITE and PAS/GMS to rule out infection